

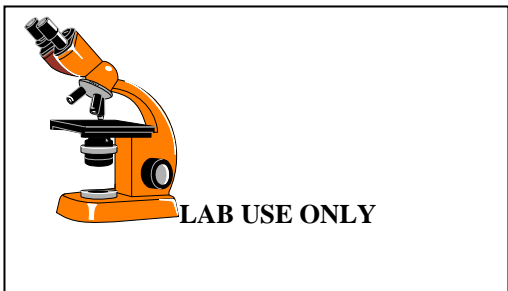
**WOMEN'S INTERAGENCY HIV STUDY
LABORATORY - LABORATORY PAP SMEAR FORM
FORM C60**

PARTICIPANT ID: | | | - | | | | | - | | | | | | | | - | | |

VISIT #: | | | |

FORM COMPLETED BY: | | | | | |

VERSION DATE: **10/01/15**



ANY MISSING OR INCOMPLETE TEST RESULTS MUST BE EXPLAINED ON THIS FORM.

A1. Date specimen obtained: ___/___/___
M D Y

A2. Date central reading: ___/___/___
M D Y

A3. Specimen site (circle one):
Cervical smear..... 1
Vaginal smear..... 2
Not given..... 3

A4. Specimen adequacy (circle one):
Satisfactory..... 1 (A5)
Unsatisfactory 3

Reason: _____ (END)

A5. Endocervical component
YES 1
NO 2

A6c. Trichomonas present
YES 1
NO 2

INFLAMMATION: Y N

A7. Inflammation present 1 2

SCORE: 1+ 2+ 3+ 4+

DO NOT DATA ENTER INFO IN TABLE BELOW

Candida	
Other	
Comment:	
CT/Date	CT/Date
PATH/Date	

A11a. Cervical cells within normal limits
YES..... 1 (A14)
NO 2

EPITHELIAL CELL:

A11. Squamous cell(s) Y N
b. ASC -US 1 2
c. ASC -HGSIL..... 1 2
d. LGSIL: mild (slight) dysplasia/CIN1/HPV 1 2
e. HGSIL: moderate dysplasia/CIN2..... 1 2
f. HGSIL: severe
dysplasia/CIN3/carcinoma in situ 1 2
g. HGSIL: features of invasion 1 2
h. Squamous cell carcinoma..... 1 2

A12. Glandular cell(s) Y N
b. Atypical gland. cells (unqualified)..... 1 2
c. Atypical gland. cells (favor neoplastic) 1 2
d. Adenocarcinoma in situ 1 2
e. Adenocarcinoma 1 2

SPECIFY PROBABLE ORIGIN SITE:

f. Other malignant epithelial neoplasm 1 2

SPECIFY: _____

A13. Non-epithelial malignant neoplasm present ... 1 2

A14. Presence of endometrial cells in woman > 45YO?

YES..... 1
NO..... 2
NA 3

A15. Thin-prep Pap?

YES..... 1
NO..... 2