WOMEN'S INTERAGENCY HIV STUDY
LABORATORY - LABORATORY PAP SMEAR FORM
FORM C60

PARTICIPANT ID: |___|-|___|___|-|___|___|___|___|-|___|

VISIT #: |___|___|

FORM COMPLETED BY: |___|___|___|

VERSION DATE: **0 4 / 0 1 / 1 1**

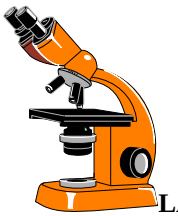

LAB USE ONLY

ANY MISSING OR INCOMPLETE TEST RESULTS MUST BE EXPLAINED ON THIS FORM.

A1. Date specimen obtained: ___ ___/___ ___/___ ___
M D Y

A2. Date central reading: ___ ___/___ ___/___ ___
M D Y

A3. Specimen site (circle one):

Cervical smear.....1
Vaginal smear.....2
Not given.....3

A4. Specimen adequacy (circle one):

Satisfactory.....1 **(A5)**
Unsatisfactory 3

Reason: _____ **(END)**

A5. Endocervical component

YES 1
NO.....2

INFLAMMATION:	Y	N
A7. Inflammation present	1	2

SCORE: 1+ 2+ 3+ 4+

DO NOT DATA ENTER INFO IN TABLE BELOW

Trichomonas	
Candida	
Other	
Comment:	
CT/Date	CT/Date
PATH/Date	

EPITHELIAL CELL:

A11. Squamous cell(s)	Y	N
a. Within normal limits.....	1	2
b. ASC -US	1	2
c. ASC -HGSIL.....	1	2
d. LGSIL: mild (slight) dysplasia/CIN1/HPV	1	2
e. HGSIL: moderate dysplasia/CIN2.....	1	2
f. HGSIL: severe dysplasia/CIN3/carcinoma in situ.....	1	2
g. HGSIL: features of invasion	1	2
h. Squamous cell carcinoma	1	2

A12. Glandular cell(s)	Y	N
a. Presence of endometrial cells in postmenopausal woman > 40YO.....	1	2
b. Atypical gland. cells (unqualified).....	1	2
c. Atypical gland. cells (favor neoplastic)	1	2
d. Adenocarcinoma in situ	1	2
e. Adenocarcinoma	1	2

SPECIFY PROBABLE ORIGIN SITE:

_____

f. Other malignant epithelial neoplasm	1	2

SPECIFY: _____

A13. Non-epithelial malignant neoplasm present....	1	2