

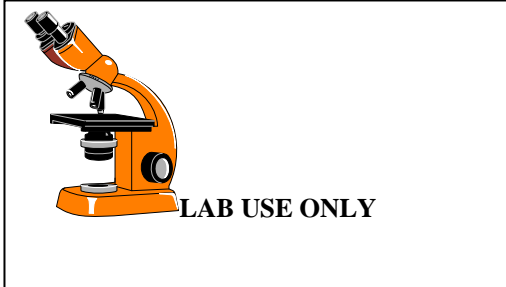
**WOMEN'S INTERAGENCY HIV STUDY  
LABORATORY - LABORATORY PAP SMEAR FORM  
FORM C60**

PARTICIPANT ID: \_\_\_\_\_

VISIT #: \_\_\_\_\_

FORM COMPLETED BY: \_\_\_\_\_

VERSION DATE: **11/01/13**



**ANY MISSING OR INCOMPLETE TEST RESULTS MUST BE EXPLAINED ON THIS FORM.**

A1. Date specimen obtained: \_\_\_\_\_/\_\_\_\_\_/\_\_\_\_\_  
M D Y

A2. Date central reading: \_\_\_\_\_/\_\_\_\_\_/\_\_\_\_\_  
M D Y

A3. Specimen site (circle one):  
Cervical smear..... 1  
Vaginal smear..... 2  
Not given..... 3

A4. Specimen adequacy (circle one):  
Satisfactory..... 1 (A5)  
Unsatisfactory ..... 3  
Reason: \_\_\_\_\_ (END)

A5. Endocervical component  
YES ..... 1  
NO ..... 2

INFLAMMATION: \_\_\_\_\_ Y N

A7. Inflammation present ..... 1 2  
SCORE: 1+ 2+ 3+ 4+

**DO NOT DATA ENTER INFO IN TABLE BELOW**

Trichomonas	
Candida	
Other	
Comment:	
CT/Date	CT/Date
PATH/Date	

A11a. Within normal limits  
YES..... 1 (A14)  
NO ..... 2

**EPITHELIAL CELL:**

A11. Squamous cell(s) Y N  
b. ASC -US ..... 1 2  
c. ASC -HGSIL..... 1 2  
d. LGSIL: mild (slight) dysplasia/CIN1/HPV .... 1 2  
e. HGSIL: moderate dysplasia/CIN2 ..... 1 2  
f. HGSIL: severe  
dysplasia/CIN3/carcinoma in situ ..... 1 2  
g. HGSIL: features of invasion ..... 1 2  
h. Squamous cell carcinoma ..... 1 2

A12. Glandular cell(s) Y N  
a. Presence of endometrial cells in  
postmenopausal woman > 40YO ..... 1 2  
b. Atypical gland. cells (unqualified)..... 1 2  
c. Atypical gland. cells (favor neoplastic) ..... 1 2  
d. Adenocarcinoma in situ ..... 1 2  
e. Adenocarcinoma ..... 1 2

**SPECIFY PROBABLE ORIGIN SITE:**

f. Other malignant epithelial neoplasm ..... 1 2  
SPECIFY: \_\_\_\_\_

A13. Non-epithelial malignant neoplasm present.... 1 2

A14. Thin-prep Pap?  
YES..... 1  
NO..... 2